Leprosy: a primer for Canadian physicians

Andrea K. Boggild, Jay S. Keystone, Kevin C. Kain

ß See related article page 55

Abstract

LEPROSY IS A RARE BUT SERIOUS INFECTIOUS DISEASE caused by *Mycobacterium leprae*. While global prevalence of the disease is decreasing, increasing rates of immigration from countries where leprosy is endemic have led to the recognition of this illness in North America. Classically, leprosy presents as hypopigmented cutaneous macules along with sensory and motor peripheral neuropathies, although the clinical manifestations vary along a disease spectrum. In addition to primary infection, patients may undergo a "reaction," an acute inflammatory response to the mycobacterium, which leads to pain and erythema of skin lesions and dangerous neuritis. Reactions can occur at any time during the course of leprosy, but they tend to be precipitated by treatment. They are a significant cause of impaired quality of life due to marked nerve damage and thus warrant prompt intervention. Although leprosy may have a protracted onset and be difficult to recognize, cure is achievable with appropriate multidrug therapy. Because untreated leprosy can result in permanent, irreversible nerve damage and secondary transmission, early diagnosis and treatment are essential to minimize morbidity.

CMAJ 2004;170(1):71-8

Hansen's disease, also known as leprosy, may be underappreciated in Western countries. Increasing levels of immigration over the past 3 decades from countries where leprosy is endemic, such as India, Vietnam and the Philippines, have resulted in rising numbers of cases of leprosy being recognized in Canada. Leprosy, a transmissible infectious disease that can lead to profound neurologic impairment if left untreated, has implications for the infected individual and for public health. The clinical manifestations depend upon the infected person's immune response to the causative agent, *Mycobacterium leprae*. Skin lesions and peripheral nerve enlargement and impairment are the clinical hallmarks of leprosy, and prompt recognition is key to limiting morbidity due to irreversible nerve damage. Although the onset of leprosy can be insidious and the disease may be difficult to recognize, it is curable with appropriate multidrug therapy. In this review of leprosy in Canada, we emphasize the clinical manifestations of the disease and the importance of early diagnosis and treatment.

Epidemiology

Leprosy is rare in North America. In the United States, 136 to 187 cases of leprosy were reported annually between 1991 and 1995.[1] Although most cases occur in immigrants, small pockets of endemic disease exist in Texas, Hawaii and Louisiana. In Canada the prevalence of leprosy is estimated at 0.6 cases per 100 000 population.[2] Transmission of the disease within Canada's borders has not been documented. Worldwide, fewer than 1 million cases are registered annually,[2] a decrease from 5.4 million in 1985.[3] In 2001 the number of cases reported globally was 763 317, the majority of these (87.6%) occurring in Southeast Asia and India.[2] The overall decrease in prevalence has resulted from the introduction of short-course multidrug therapy, first instituted in 1982, following which many patients were removed from global registries.[4–5] The prevalence of leprosy varies greatly from country to country, but most cases occur in the developing world, with 16 nations (led by India and Brazil) accounting for 92% of all cases;[6] Southeast Asia also contributes significantly to the global caseload.

Canada's experience with leprosy dates back to 1815, when the first documented case was reported in New Brunswick.[7] In May 1891, 5 Chinese immigrants with symptomatic leprosy were forcibly removed from Victoria and taken by steamer to an island in the San Juan archipelago. This move established Canada's first true "leper colony," which existed until the last patient died in 1957.[7] Over the past 30 years, immigration from countries such as India, Vietnam and the Philippines has increased and with it the importation of diseases endemic to these regions, including leprosy. Because leprosy can have a protracted, insidious onset, it may not manifest until after the immigration process is complete, making it difficult to implement preimmigration detection and treatment. Given that the majority of new migrants with leprosy manifest the disease within 1 year of immigration,[8] it is postulated that stress[9–12] or other factors associated with migration may push the disease from quiescent to symptomatic.

Pathogenesis

M. leprae is an obligate acid-fast bacillus that tends to infect skin and peripheral nerves in cooler areas of the body such as the chin, malar eminences, earlobes, knees and distal

extremities.[13] Humans are its principal reservoir, and the disease spreads by aerosolized droplets from lepromatous patients and, less commonly, through direct skin contact.[14–19] Although these are believed to be the main modes of transmission, many patients have no identifiable contacts.[17,18]

The vast majority of the world's population is not susceptible to leprosy; however, familial clustering of leprosy has been demonstrated, and twin studies have revealed high concordance rates.[19] Susceptibility appears to be governed, at least partly, by the *nramp1* gene, which controls susceptibility to mycobacteria in mice.[20] An HLA (human leukocyte antigen) association appears to play a role in the clinical spectrum of disease, with the HLA-DR3 genotype overrepresented in tuberculoid leprosy and the HLA genotype DQ1 or MT1 more likely to be seen in lepromatous disease.[21]

Classification of disease

The manifestations of leprosy depend upon the infected person's immune response to the causative agent, *M. leprae*. Genetic susceptibility determines whether disease will develop in an exposed individual and, if so, how the infection will manifest.

In an exposed person who is susceptible to leprosy, a single skin lesion may develop after an incubation period averaging 2 to 4 years (range 3 months to 40 years).[22] This initial stage is called indeterminate leprosy, and in many patients, the lesion heals spontaneously. If healing does not occur, then the disease progresses along a clinical spectrum (Fig. 1). A patient's place along this spectrum depends on the interaction between the organism and his or her specific immune response to infection.[13,23–28] The stages of the spectrum, in order of decreasing cell-mediated immune response to *M. leprae*, are tuberculoid leprosy (TT), characterized by few skin lesions and low bacterial loads, borderline tuberculoid leprosy (BT), borderline leprosy (BB), borderline lepromatous leprosy (BL) and lepromatous leprosy (LL), characterized by diffuse skin lesions and high bacterial loads (Fig. 1). Leprosy can also be classified according to the number of skin lesions present and the number of bacilli found on slit-skin smear examination. Paucibacillary disease (indeterminate, TT and BT forms) is defined as fewer than 6 skin lesions with no bacilli on slit-skin smear testing.[25] Multibacillary disease (BB, BL and LL forms) is characterized by 6 or more lesions with or without positive skin smear results.[25]

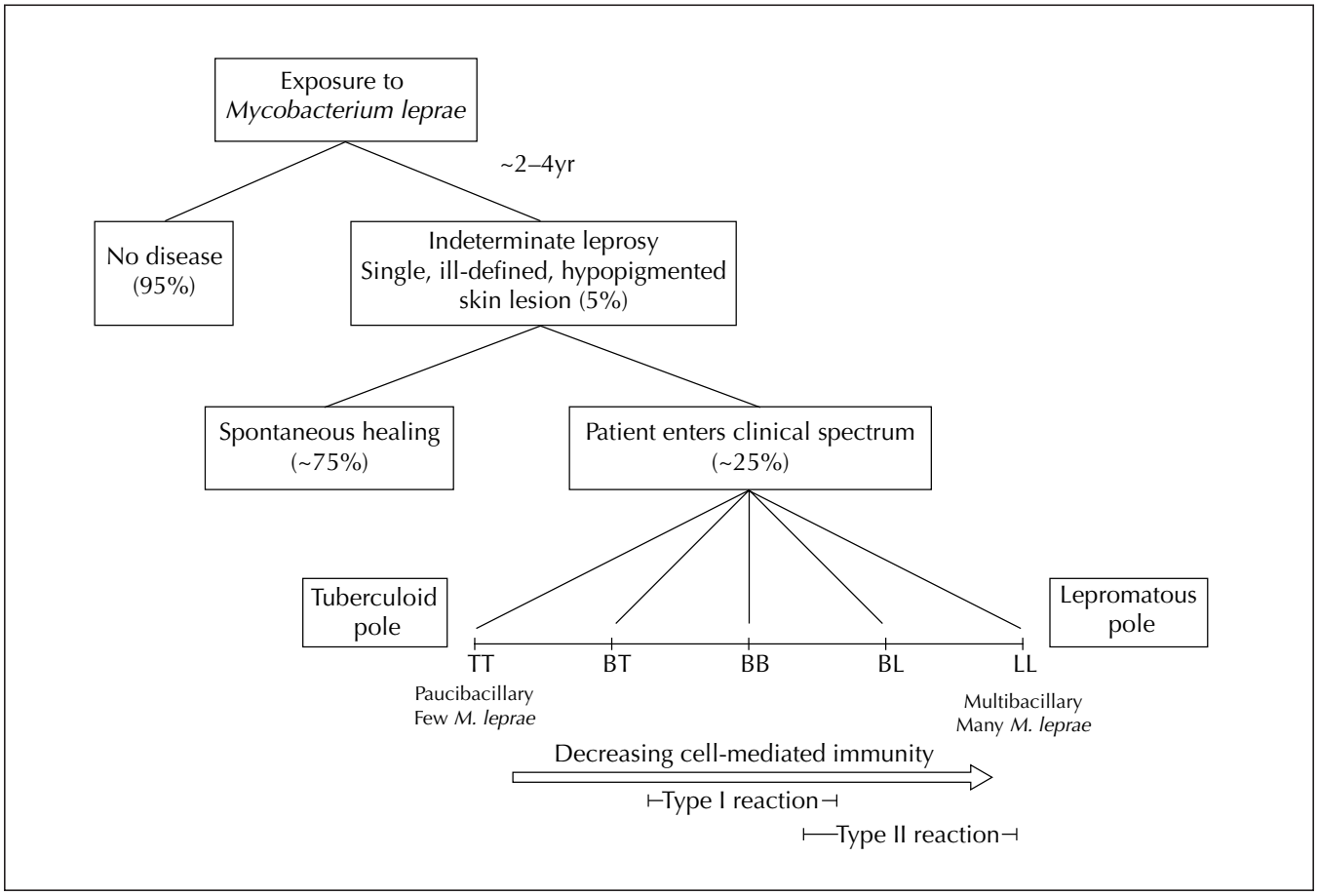

Fig. 1: Clinical spectrum of leprosy. CMI = cell-mediated immunity, TT = tuberculoid leprosy, BT = borderline tuberculoid leprosy, BB = borderline leprosy, BL = borderline lepromatous leprosy, LL = lepromatous leprosy.

Clinical features

Clinically, leprosy may resemble many dermatologic and neurologic conditions; thus, a high index of suspicion is necessary for accurate diagnosis.[13,26–28] Leprosy typically presents with anesthetic skin lesions associated with thickened peripheral nerves. The appearance of the skin lesions varies according to the spectrum of disease (Table 1).

The lesions of indeterminate leprosy tend to be hypopigmented and ill-defined, and they heal on their own in approximately 75% of cases; consequently, they are ignored by many patients.[13]

Patients at the tuberculoid pole of the disease spectrum typically present with just a few (less than 6) asymmetrically distributed, well-circumscribed skin lesions, with elevated margins and marked hypopigmentation[13] (Fig. 2A). The lesions have a dry, scaly appearance, with impairment of sweating because of disruption of autonomic nerve function; they are typically hairless and anesthetic. Enlargement of a single nerve is common, and marked nerve damage can occur early in the course of tuberculoid disease, often resulting in wrist drop, clawing of the hand and foot drop.[13] Tuberculoid leprosy often involves the greater auricular, radial cutaneous, ulnar, common peroneal and posterior tibial nerves.[13] Early treatment is key to minimizing nerve damage.

Patients at the lepromatous pole present with skin lesions that are widely and symmetrically disseminated, often demonstrating only slight hypopigmentation or erythema[13] (Fig. 2B). The lesions have a smooth, shiny surface, and impaired sweating and hair growth are late features, as is loss of sensation. Nerve damage tends to be slow but progressive. Hypoesthesia often occurs first over the extensor surfaces of the legs, feet, forearms and hands.[13] Weakness occurs distally, beginning with the intrinsic muscles of the hands and feet.[13] If untreated, lepromatous disease progresses, and the affected skin begins to thicken, predominantly in the forehead, earlobes, eyebrows and cheeks, which eventually leads to the classic leonine (lion-like) facies.[13]

In the middle of the spectrum, the borderline forms reflect an unstable balance between cell-mediated immunity and bacterial replication and can progress unpredictably toward either pole.[13] Skin lesions are abundant, with various degrees of symmetry, definition and pigmentation[13] (Fig. 2C). The nerves are often affected irregularly and asymmetrically, and anesthesia is an early sequela of borderline disease.[13]

In addition to their primary infection, patients with leprosy can experience episodic immunologically mediated acute inflammatory responses termed "reactions," which are important mechanisms for nerve damage. For this reason a leprosy reaction should be considered a medical emergency requiring immediate attention. During a reaction, the skin lesions often become swollen, erythematous and tender, while the accompanying neuritis leads to pain, tenderness and loss of function[13] (Figs. 2D, 2E). These reactions, which occur in up to one-third of patients,[4] contribute to leprosy-associated morbidity by causing irreversible nerve damage and limb deformity. There are 2 common types of leprosy reactions: type I or reversal reactions, characterized by cellular hypersensitivity, and type 2 or erythema nodosum leprosum (ENL), characterized by a systemic inflammatory response to immune complex deposition.

A type I reaction implies a change in cell-mediated immunity and often a corresponding shift of borderline leprosy toward the tuberculoid pole. These reversal reactions typically occur after initiation of leprosy treatment but may occur spontaneously before therapy.[13] Reversal reactions are dangerous, in that the nerve damage may be asymptomatic and may progress "silently" for prolonged periods.[4] In addition to treatment, other precipitants of type I reactions include puberty, pregnancy and parturition.[4,13]

Table 1: Classic clinical features of tuberculoid and lepromatous leprosy

Type of lesion	Tuberculoid	Lepromatous
Skin	Lesions few, distributed asymmetrically	Macules and lesions widely and symmetrically distributed
	Well circumscribed	Skin of forehead, cheeks and earlobes thickens; loss of lateral eyebrows
	Hypopigmentation	Slight hypopigmentation or erythema
	Dry, scaly appearance	Smooth, shiny surface
	Hairless, anesthetic	Late impairment of sweating or sensation
Nerve	Single nerve enlargement	Damage slow but progressive
	Marked, early damage	Hypoesthesia over extensor surfaces of legs, feet, forearms, hands
	Greater auricular, radial cutaneous, ulnar, common peroneal, posterior tibial nerves commonly affected	Distal weakness begins with intrinsic muscles of hands and feet

ENL, characterized by humoral hypersensitivity, occurs in patients with lepromatous leprosy and often presents with crops of tender, subcutaneous nodules, fever, arthralgia, neuralgia and occasionally vasculitis, adenopathy, orchitis and dactylitis[4] (Fig. 2F). ENL can be triggered by treatment, vaccination, tuberculin skin testing and other stimulants of the immune system.[29]

These 2 types of immunologic reactions, as well as nerve damage from progressive *M. leprae* infection itself, lead to impaired function of sensory, autonomic and motor nerves. Anesthetic limbs are subject to repeated trauma, pressure necrosis and secondary infection, all of which culminate in the loss of digits and limb deformity that are classically associated with leprosy. Autonomic disruption leads to dry skin that easily fissures and ulcerates, and loss of the protective corneal reflex (because of damage to the trigeminal nerve) can lead to blindness.[13] Common motor findings in late disease include clawing of the hand, wrist drop and foot drop due to destruction of the ulnar, radial cutaneous and common peroneal nerves respectively.

Diagnosis and treatment

Early diagnosis of subclinical or carrier-state leprosy has been problematic. Even though *M. leprae* can be detected in the nasal mucosa of people who have been exposed to leprosy, this finding predicts neither clinical disease nor infectivity.[4]

The diagnosis of other forms of leprosy is usually made on clinical grounds (i.e., the finding of anesthetic skin le-

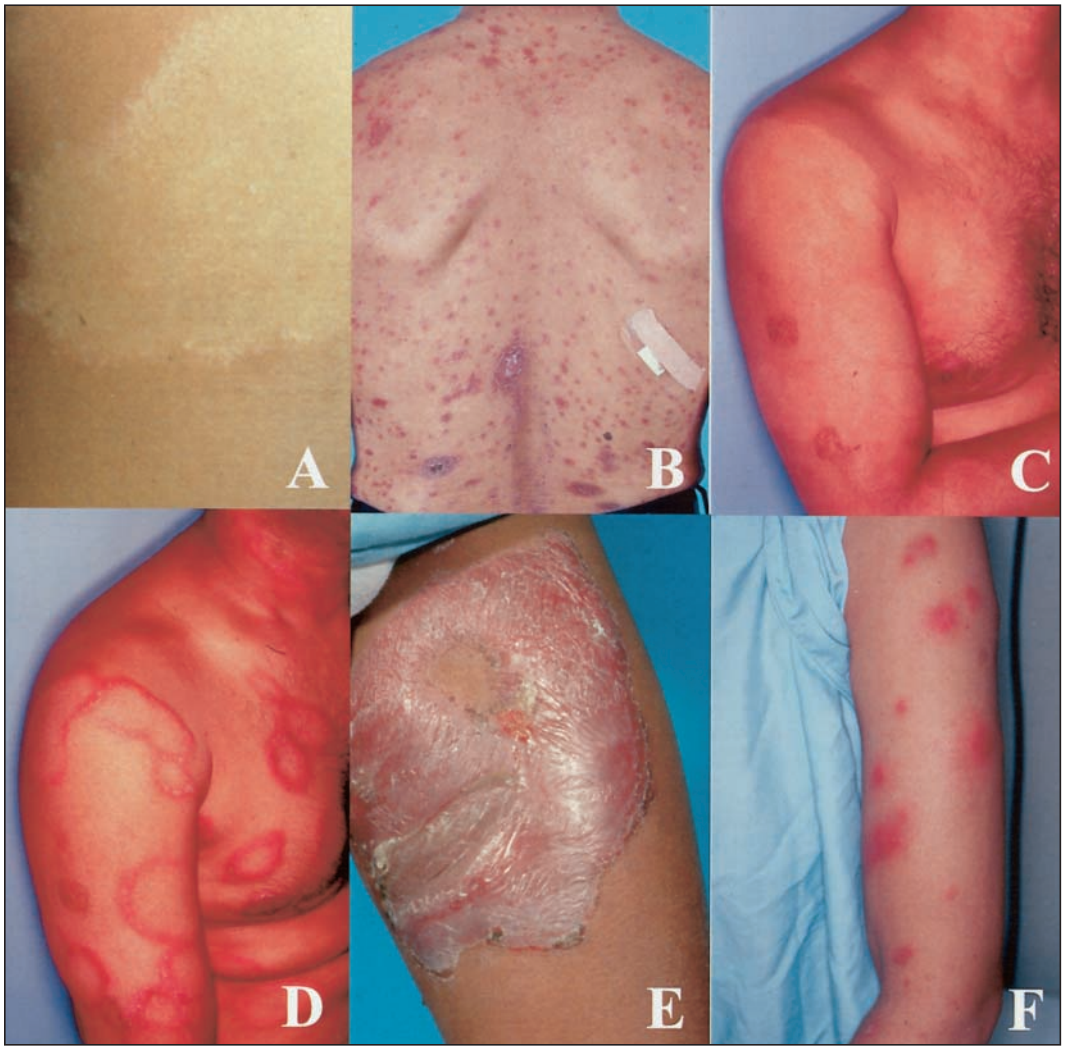

Fig. 2: Clinical signs associated with leprosy in various stages of the disease. A: Large hypopigmented macule of TT leprosy. B: BL leprosy. C: BB leprosy before therapy. D: The same patient as in Fig. 2C undergoing a type I reversal reaction during therapy. Note the accentuation and erythema of macules relative to Fig. 2C. E: Patient with BT leprosy undergoing a type I reversal reaction. F: Patient with LL leprosy undergoing a type II reaction (erythema nodosum leprosum). Note the raised, erythematous crops of nodules.

sions in the presence of thickened peripheral nerves); however, demonstration of acid-fast bacilli in slit-skin smears provides laboratory confirmation of the diagnosis in cases of multibacillary disease. Samples for skin smears are obtained by scraping with a scalpel blade the opening of small slits made in pinched skin. The tissue fluid obtained is smeared on a slide and stained for acid-fast bacilli by Fite's method.[27] Serologic testing has little clinical utility in diagnosing leprosy. Skin biopsy is another method of diagnosing leprosy, especially in patients with paucibacillary disease, in which acid-fast bacilli are scant, and it can be used to classify the disease according to the clinical spectrum. Although bacilli are often not seen at the tuberculoid end of the spectrum, the finding of inflamed nerves usually clinches the diagnosis.

Key points: Pathogenesis

- *Mycobacterium leprae* is an acid-fast bacillus
- Bacilli target skin and peripheral nerves in cooler areas of the body
- Humans are the principal reservoir
- Transmission is by aerosolized droplets or direct skin contact
- Most people are not susceptible

Treating leprosy and its reactions can be challenging, and the disease is best managed by a tropical disease specialist or a dermatologist with specific expertise in this area. Leprosy is a reportable disease, so if it is suspected, the public health department should be notified and a specialist consulted. Multidrug therapy has been the standard for treatment of leprosy since 1982.[28] Currently recommended regimens include a combination of rifampin, dapsone and clofazimine (Tables 2 and 3). Of these drugs, rifampin is the most effective bactericidal agent against *M. leprae*, killing 99.99% of organisms with a single dose.[4] This drug may thus be administered as infrequently as once per month, and patients are rendered noninfectious within 1 to 2 weeks.

Patients with paucibacillary disease are generally treated with double therapy for 6 months, whereas multibacillary leprosy generally necessitates a 2-year course of triple therapy, even though current World Health Organization guidelines[25] suggest that 1 year of triple therapy may be sufficient. Suggested follow-up is for 5 to 10 years after treatment is complete.

Recent clinical trials have also assessed the efficacy of single-dose therapy (with rifampin, ofloxacin and minocycline) for the treatment of single-lesion paucibacillary leprosy. In one large multicentre trial, 1483 patients with one skin lesion were randomly assigned to receive either the single-dose regimen of rifampin, ofloxacin and minocycline or the standard 6-month multidrug therapy. Only 12 treatment failures had occurred by the end of the 18-month follow-up, and there was no difference between the 2 groups.[30] This single-dose strategy is currently being implemented in India and other areas where leprosy is endemic.

The inflammatory component of reactions makes them difficult to control. Type I reactions are best managed with 40 to 60 mg of prednisone daily to start, followed by a tapering dose once the reaction begins to subside, usually over several months. If nerve damage is already present, then 3 to 6 months of corticosteroid therapy is typical, although the response rate to this form of management is generally less than 65%.[31] Type II reactions (ENL) are best treated with prednisone or thalidomide, each of which has distinct advantages and disadvantages. Although clofazimine has only a minor role in the acute management of ENL, it is particularly useful in chronic cases as a steroid-sparing agent.[3] Conversely, if neuritis is present initially, a corticosteroid is always warranted. Thalidomide at a dose of 300 to 400 mg daily usually controls ENL reactions within several days of initiation of therapy.[3] The drug is then tapered to a maintenance dose of 100 mg per day for as long as necessary. The utility of thalidomide is limited by its restricted availability, its cost and its teratogenicity.

Table 2: Current World Health Organization[25] recommendations for multidrug treatment of leprosy

Classification of disease	Drug	Dosage	Duration
Paucibacillary (I, TT, BT)	Rifampin	600 mg once monthly, supervised	6 mo
	Dapsone	100 mg daily, self-administered	6 mo
Single-lesion, paucibacillary	Rifampin	600 mg	Once
	Ofloxacin	400 mg	Once
	Minocycline	100 mg	Once
Multibacillary (BB, BL, LL)	Rifampin	600 mg once monthly, supervised	12 mo
	Dapsone	100 mg daily, self-administered	12 mo
	Clofazimine	300 mg once monthly, supervised or 50 mg daily, self-administered	12 mo

Note: I = indeterminate disease, TT = tuberculoid leprosy, BT = borderline tuberculoid leprosy, BB = borderline leprosy, BL = borderline lepromatous leprosy, LL = lepromatous leprosy.

Key points: Leprosy reactions

- Occur in addition to primary infection
- Significant cause of morbidity because of nerve damage
- Two types: type 1 (reversal reaction) and type 2 (erythema nodosum leprosum)
- Characterized by increased swelling and pain of skin lesions accompanied by neuritis, which together lead to loss of nerve function

It is important to recognize the role of self-care in the management of leprosy patients with anesthesia. Because the risk of limb loss is directly related to unrecognized trauma, an emphasis on vigilance is warranted. Daily foot care in the form of inspection is advised, and chiropody services can be used liberally. Surgical correction of clawed hands, dropped wrists and lagophthalmos often results in significant functional improvement.

Prognosis

Response to treatment is generally good, and neurologic deficits are often at least partially ameliorable with early treatment. Skin lesions typically resolve within the first year after completion of multidrug therapy, although skin lesions may persist for up to 5 years in cases of multibacillary disease because more time is needed to clear dead bacteria from the body.[3] Once multidrug therapy has been stopped, relapse or reaction may occur. Relapse is distinct from the type I and type II reactions described above, in that it occurs only in patients who have received adequate multidrug therapy, following which they present with new skin or nerve lesions. It is important to distinguish relapse from reaction, because the management is different. From 0.01% to 0.14% of patients relapse annually within the first 10 years; hence the need for protracted follow-up.[4] Similarly, within the first year after completion of multidrug therapy, 5% to 10% of patients can be expected to undergo a type 1 reversal reaction, so careful follow-up every 3 months for the first year after treatment is advised.[4]

Special considerations

Unlike the situation for tuberculosis, the case detection rate and treatment outcome for leprosy appear to have been influenced little by the global AIDS pandemic.[32,33] Fortunately, the immunodeficiency associated with HIV-1 infection has not generally translated into a more complicated course for patients coinfected with *M. leprae*. Conversely, pregnancy, which leads to depressed cell-mediated immunity, can precipitate leprosy reactions or relapse in

Table 3: Summary of drugs used in the treatment of leprosy

Drug	Indication	Mechanism	Side effects	Cost,* $
Rifampin	Paucibacillary, multibacillary	Bactericidal, RNA-Pol inhibitor	GI: abdominal pain, nausea, vomiting, diarrhea	2.60/300 mg
			Dermatologic: pruritus, rash	
			Renal: acute renal failure pseudohematuria	
			Hepatic: transient liver dysfunction, jaundice, induction of P450 enzymes	
Dapsone	Paucibacillary, multibacillary	Bacteriostatic, antifolate	Dermatologic: rash	0.48/100 mg
			Hematologic: agranulocytosis, hemolysis (severe if G6PD deficient), methemoglobinemia	
			Other: drug fever	
Clofazimine	Multibacillary	Bacteriostatic, binds *M. leprae* DNA	Dermatologic: skin pigmentation that often resolves with drug cessation	0.27/50 mg
			GI: upset	
Ofloxacin	Single-lesion paucibacillary	Bactericidal, DNA gyrase inhibitor	GI: nausea	7.63/400 mg
			Dermatologic: rash, pruritus, photosensitivity	
			CNS: seizures, headache, dizziness	
Minocycline	Single-lesion paucibacillary	Bacteriostatic, inhibits protein synthesis via 30S	GI: upset, hepatotoxicity	1.02/100 mg
			Dermatologic: photosensitivity	
			Other: dental staining; therefore contraindicated in pregnant women, neonates, children < 8 yr old	

Note: RNA-Pol = RNA polymerase, a necessary enzyme in cellular transcription; GI = gastrointestinal; G6PD = glucose-6-phosphate dehydrogenase; CNS = central nervous system; 30S = small subunit of ribosome necessary for translation of mRNA.
*Source: www.drugstore.com; original values in US dollars, conversion factor 1.40.

treated patients.[34] Type 2 reactions are particularly common in pregnant patients under the age of 40 years. Although both types of reactions can occur in pregnant women, ENL is particularly difficult to manage because of the teratogenicity of thalidomide, the drug of choice. For pregnant leprosy patients not undergoing reaction, dapsone and clofazimine are generally thought to be safe; however, adequate data supporting use of rifampin in pregnancy are lacking.[3] Children with leprosy also need special consideration. Unlike leprosy that manifests in adulthood (which occurs more frequently in men), childhood leprosy demonstrates no difference in preponderance between the sexes.[35] In addition, multibacillary disease (BB, BL and LL forms) is uncommon in children, as are reactions.[35–37]

Leprosy: the future

Although global eradication of leprosy is a definite aim for the future, numerous challenges remain. First, case detection is largely passive, even in countries of hyperendemicity.[3] Public health programs have historically focused on educating the public about the signs and symptoms of leprosy and have then relied on patients to present themselves once they become symptomatic.[3] Multidrug therapy has reduced the prevalence rate of leprosy, but the incidence rate has remained relatively stable because this form of therapy has little effect on transmission of leprosy within households.[38] In addition, the prevention of leprosy has proved challenging. Chemoprophylaxis with rifampin or dapsone for high-risk contacts of leprosy patients has been unsuccessful.[39] In fact, the only prophylactic measure with any degree of success has been vaccination with BCG (bacille Camille-Guérin), with one dose conferring approximately 50% protection.[40,41]

Given that leprosy will persist in countries where it is not easily diagnosed and treated, and in the context of unprecedented mobility of people around the globe, cases of imported leprosy are likely to continue to occur in Canada. Thus, it is important for Canadian health care providers to be aware of the diagnosis and management of this disease. Foreseeable barriers to the accurate diagnosis and treatment of imported leprosy in Canada include delays in seeking care secondary to language barriers,[42] poor socioeconomic status and stigmatization of leprosy within certain communities; fragmentation of care through the immigration process;[42] lack of disease awareness leading to misdiagnosis;[43] and poor long-term follow-up of infected patients.

In summary, leprosy is a rare but serious mycobacterial disease, with potentially severe neurologic sequelae if left untreated. Leprosy should be considered in the differential diagnosis of patients with chronic dermatitis and peripheral nerve involvement who have a history of prolonged travel to or residence in a country where the disease is endemic. Leprosy is curable with appropriate chemotherapy and follow-up. Therefore, if this diagnosis is suspected, the patient should be referred promptly to a specialist with experience in managing leprosy.

This article has been peer reviewed.

From the Faculty of Medicine, University of Toronto (Boggild, Keystone, Kain), and the Tropical Disease Unit, University Health Network – Toronto General Hospital (Keystone, Kain), Toronto, Ont.

Competing interests: None declared.

Contributors: Andrea K. Boggild, Jay S. Keystone and Kevin C. Kain were all involved in the conception, design and writing of this manuscript.

References

1. Centers for Disease Control and Prevention. Summary of notifiable diseases, United States, 1995. *MMWR Morb Mortal Wkly Rep* 1995;44:73.
2. World Health Organization. Leprosy, global situation. *Wkly Epidemiol Rec* 2002;77:1–8.
3. Jacobson RR, Krahenbuhl JL. Leprosy. *Lancet* 1999;353:655–60.
4. Ooi WW, Moschella SL. Update on leprosy in immigrants in the United States: status in the year 2000. *Clin Infect Dis* 2001;32:930–7.
5. Fine PE. Reflections on the elimination of leprosy. *Int J Lepr Other Mycobact Dis* 1992;60:71–80.
6. World Health Organization. Progress towards leprosy elimination. *Wkly Epidemiol Rec* 1998;73:153–60.
7. Johnston P. BC's "Island of Death" marked a sad chapter in Canada's medical history. *CMAJ* 1995;152(6):951–2.
8. Neill MA, Hightower AW, Broome CV. Leprosy in the United States, 1971–1981. *J Infect Dis* 1985;152:1064-9.
9. Brodov Y, Mandelzweig L, Boyko V, Behar S. Is immigration associated with an increase in risk factors and mortality among coronary artery disease patients? A cohort study of 13,742 patients. *Isr Med Assoc J* 2002;4:326-30.
10. Hattar-Pollara M, Meleis A. The stress of immigration and the daily lived experiences of Jordanian immigrant women in the United States. *West J Nurs Res* 1995;17:521-39.
11. Ritsner M, Ponizovsky A. Psychological distress through immigration: The two-phase temporal pattern? *Int J Soc Psychiatry* 1999;45:125-39.
12. Zulman A. The hidden trauma of immigration. *Aust Fam Physician* 1996;25:1707-10.
13. Bryceson A, Pfaltzgraff RE. Clinical pathology, symptoms and signs. In: Hastings RC, editor. *Leprosy. Medicine in the tropics*. 3rd ed. Edinburgh: Churchill Livingstone; 1990. p. 11-55.
14. Blake LA, West BC, Lary CH, Tdd JR 4th. Environmental nonhuman sources of leprosy. *Rev Infect Dis* 1987;9:562-77.
15. Thomas DA, Mines JS, Thomas DC, Mack TM, Rea TH. Armadillo exposure among Mexican born patients with lepromatous leprosy. *J Infect Dis* 1987;156:990-2.
16. Filice GA, Greenberg RN, Fraser DW. Lack of observed association between armadillo contact and leprosy in humans. *Am J Trop Med Hyg* 1977;26:137-9.
17. Enna CD, Jackson RR, Trautman JR, Sturdivant M. Leprosy in the United States, 1967–76. *Public Health Rep* 1978;93:468-73.
18. Joseph BZ, Yoder LJ, Jacobson RR. Hansen's disease in native-born citizens of the United States. *Public Health Rep* 1985;100:666-71.
19. Chakravartii MR, Vogel F. *A twin study on leprosy*. Stuttgart, Germany: Georg Thieme; 1973.
20. Abel L, Sanchez FO, Oberti J, Thuc NV, Hoa LV, Lap VD, et al. Susceptibility to leprosy is linked to the human *NRAMP1* gene. *J Infect Dis* 1998;177:133-45.
21. de Vries RRP, Ottenhoff THM. Immunogenetics of leprosy. In: Hastings RC, editor. *Leprosy*. 2nd ed. Edinburgh: Churchill Livingstone; 1994. p. 113-21.
22. Noussitou FM, Sansaricq H, Walter J. *Leprosy in children*. Geneva: World Health Organization; 1976.
23. Ridley DS, Jopling WH. Classification of leprosy according to immunity. *Int J Lepr Other Mycobact Dis* 1966;34:255-73.
24. Sehgal VN, Srivastava G. Indeterminate leprosy: a passing phase in the evolution of leprosy. *Lepr Rev* 1987;58:291-9.
25. WHO Expert Committee on Leprosy. *7th report*. no. 874 of *Technical Report* series. Geneva: World Health Organization; 1998.
26. Abulafia J, Vignale RA. Leprosy: pathogenesis updated. *Int J Dermatol* 1999;38:321-34.
27. Ridley DS, Job CK. The pathology of leprosy. In: Hastings RC, editor. *Leprosy*. New York: Churchill Livingstone; 1985. p. 129.
28. WHO Study Group on Leprosy. *Chemotherapy of leprosy control programmes*. no. 675 of *Technical Report* series. Geneva: World Health Organization; 1982.
29. Sampaio EP, Duppre NC, Nery JA, Moreira AL, Sarno EN. Development of giant reaction in response to PPD skin test in lepromatous leprosy patients. *Int J Lepr Other Mycobact Dis* 1993;61:205-13.
30. Efficacy of single dose multidrug therapy for the treatment of single-lesion paucibacillary leprosy. Single-lesion Multicentre Trial Group. *Indian J Lepr* 1997;69:121-9.

31. Croft RP, Richardus JH, Smith WCS. Field treatment of acute nerve function impairment in leprosy using a standardized corticosteroid regimen — first year's experience with 100 patients. *Lepr Rev* 1997;68:316-25.
32. Blum L, Flageul B, Sow S, Launois P, Vignon-Pennamen MD, Coll A, et al. Leprosy reversal reaction in HIV-positive patients. *Int J Lepr Other Mycobact Dis* 1993;61:214-7.
33. Lienhardt C, Kamate B, Jamet P, Tounkara A, Faye OC, Sow SO, et al. Effect of HIV infection on leprosy: a three-year survey in Bamako, Mali. *Int J Lepr Other Mycobact Dis* 1996;64:383-91.
34. Duncan ME, Melson R, Pearson JM, Ridley DS. The association of pregnancy and leprosy. I: New cases, relapse of cured patients and deterioration in patients on treatment during pregnancy and lactation — results of a prospective study of 154 pregnancies in 147 Ethiopian women. *Lepr Rev* 1981;52:245-62.
35. Bhattacharya SN, Sehgal VN. Leprosy in India. *Clin Dermatol* 1999;17:159-70.
36. Keeler R, Deer RD. Leprosy in children aged 0–4 years: report of 11-year-old control programme. *Lepr Rev* 1985;56:239-48.
37. Sehgal VN, Chaudhary AK. Leprosy in children: a prospective study. *Int J Dermatol* 1993;32:194-7.
38. Palanisamy V, Kumar J, Natarajan MM, Mozhi NM, Samuel JD. Does MDT arrest transmission of leprosy to household contacts? *Int J Lepr Other Mycobact Dis* 1998;66:125-30.
39. WHO Study Group on Leprosy. Chemotherapy of leprosy. no. 847 of *Technical Report* series. Geneva: World Health Organization; 1994.
40. Karonga Prevention Trial Group. Randomized controlled trial of single BCG, repeated BCG, or combined BCG and killed *Mycobacterium leprae* vaccine for prevention of leprosy and tuberculosis in Malawi. *Lancet* 1996;348:17-24.
41. Bertolli J, Pangi C, Prerichs R, Halloran ME. A case-control study of the effectiveness of the BCG vaccine for preventing leprosy in Yangon, Myanmar. *Int J Epidemiol* 1997;26:888-96.
42. Garrett CR, Treichel CJ, Ohmans P. Barriers to health care for immigrants and non-immigrants: a comparative study. *Minn Med* 1998;81:52-5.
43. Goldenring JM, Castle GF. Leprosy in teenage immigrants. Case reports and clinical review. *J Adolesc Health Care* 1984;5:53-5.

Correspondence to: *Dr. Kevin C. Kain, Toronto General Hospital, 200 Elizabeth St., ES-9-412, Toronto ON M5G 2C4; fax 416 595–5826; Kevin.Kain@uhn.on.ca*