Powassan encephalitis: a case report with neuropathology and literature review

Education

Éducation

Bassam I.A. Gholam,* MD; Serge Puksa,* MD; John P. Provias,† MD

From *the Department of Medicine, McMaster University, and †the Hamilton General Hospital, Hamilton, Ont.

This article has been peer reviewed.

CMAJ 1999;161(11):1419-22

A previously healthy, 64-year-old man presented on Sept. 7, 1997, with a history of headache for the past 3 days and fever (38.9°C) for the past 2 days; he had also been experiencing drowsiness and slurred speech for the past day. While camping in Algonquin Park 2 weeks before presentation the patient was bitten on the buttock by an unidentified insect. The family was concerned for a number of reasons — deer mice had been reported in the park; the family cat had accompanied the patient to the family cottage in Magnetowan, Ont., and the patient had worked under the cottage prior to camping.

On presentation the patient was oriented but drowsy and slow to respond, his temperature was 38.6°C, blood pressure 105/70 mm Hg, pulse rate 90 beats/min and respiratory rate 20 breaths/min. On neurological examination significant expressive and nominal dysphasia were noted. Mild right facial weakness was present, but there was no neck stiffness. Fine rapid movements of both hands were clumsy. Muscle tone, power, sensation and muscle stretch reflexes were normal. Initial investigations showed his leucocyte count was 12.6×10^9/L, predominantly neutrophils. Serum electrolytes, blood urea nitrogen, creatinine and glucose levels were normal, and the international normalized ratio (INR) and partial thromboplastin time (PTT) were normal. A chest x-ray showed early right lower-lobe consolidation. A CT scan (without contrast) of the head was normal. A lumber puncture revealed clear fluid, normal pressure, leukocytes $< 1 \times 10^6$, segmented neutrophils 65%, lymphocytes 32%, monocytes 3%, glucose 3.1 (normal range 2.8–4.4) mmol/L and total protein 1.75 (normally < 0.45) g/L; the Gram stain was negative. The patient was admitted with a provisional diagnosis of viral encephalitis with possible brain abscess and was started on intravenous ceftriaxone (2 g iv every 12 hours) and acyclovir (500 mg iv every 8 hours). The next day a repeat CT scan (with contrast) of the head was normal, and an echocardiogram was negative. Two days after presentation (Sept. 9) the patient began to experience right side weakness and a decreased level of consciousness, with no response to verbal or tactile stimuli. His right pupil was slightly more dilated than his left and muscle tone was flaccid, with muscle stretch reflexes 1+. The patient could not protect his airway and was intubated and transferred to the intensive care unit. Laboratory results of blood taken for viral serology (for eastern equine, western equine, St. Louis and Powassan virus antibodies and Hantavirus, rabies and Lyme disease) were negative. The following day (Sept. 10) an MRI brain scan was normal, and a lumbar puncture showed clear fluid, normal pressure, leukocytes 113×10^6, lymphocytes 60%, glucose 3.5 mmol/L and total protein 0.83 g/L. An EEG showed diffuse slowing and disorganization, and a diagnosis of viral encephalitis was established. Eight days after presentation (Sept. 15) the patient began to have episodes of awakening and was more responsive to pain and verbal requests. On September 18, 11 days after presentation, blood viral serology was positive for Powassan antibody (1/160). By September 23, the patient was more responsive; he could open his eyes and follow objects, but he was still weak and areflexic. Another CT scan (with contrast) performed on October 1 was normal. One month after presentation (Oct. 7) facial expressions were evident, and the patient was able to elevate his shoulders and bend his knees.

On Oct. 16, 1997, while sitting for physiotherapy, the patient suffered a cardiac arrest and could not be resuscitated. The cause of death determined at autopsy was a massive pulmonary embolism. The patient had received subcutaneous heparin (500 U twice daily) for deep vein thrombosis prophylaxis. Neuropathologic exami-

nation showed mild diffuse swelling of the cerebral hemispheres with diffuse meningeal congestion. Histological examination revealed an intense chronic inflammatory infiltrate in the meninges and Virchow–Robin spaces, with focal areas of infiltration into brain parenchyma in the most severe areas associated with tissue necrosis. Areas most involved were the mediotemporal lobes, ventral midbrain and basal ganglia. There was no vasculitis or true infarction. Cerebral white matter was clearly less affected and largely unremarkable, aside from secondary changes and edema. Throughout the grey matter there was diffuse reactive astrocytic gliosis, as well as microglial activation. Careful examination showed the occasional neuron with an intranuclear eosinophilic inclusion, likely representing a viral inclusion. No viral particles or inclusion structures were seen upon electron microscopic examination of brain tissue taken at the time of autopsy, although the examination was limited by sampling and postmortem artifact.

Powassan virus encephalitis: a literature review

Powassan virus was originally isolated by McLean and Donahue[1] from the brain of a 5-year-old boy who developed encephalitis and died in September of 1958. The virus was named Powassan, after the town in northern Ontario where the boy resided. Powassan virus is an arbovirus that has been isolated from 4 species of North America ticks[2,3] that belong to the genus *Ixodes*. Isolates of and antibodies to the Powassan virus have been documented in many rodents and other wild animals,[3] as well as in domestic mammals.[3–8]

Twenty-seven symptomatic cases of Powassan virus encephalitis have been reported in North America between 1958 and 1998; 23 are published[9–2], and 4 are unpublished.[23,24] Of note, 11 of the 23 cases were acquired in Canada, 7 of those in Ontario, and the majority (10/12) of cases reported in the United States originated in New York state. Although people may become infected between May and December, they are at greatest risk for Powassan viral infection between June and September.[2,3] Males (15/23) and children under the age of 15 (16/23) have been infected most frequently. Although only 7 people reported a tick bite, Ixodes ticks are small and can be easily overlooked on the human body. Two patients had contact with a known host of Powassan virus before the onset of disease,[16,25] and 1 patient owned a dog and 2 cats that were infected with ticks and possessed antibodies to Powassan virus.[4]

The reported incubation periods for Powassan virus range from 8 to 34 days. Smith and colleagues[10] reviewed the first 5 known cases of Powassan virus encephalitis and provided the following clinical picture: prodromata including sore throat, sleepiness, headache and disorientation; encephalitis characterized by vomiting, respiratory distress, possible convulsions and prolonged, sustained fever. Lethargy was common throughout the acute phase; patients were occasionally semicomatose, and some degree of paralysis was possible. Five of the diagnosed cases had focal

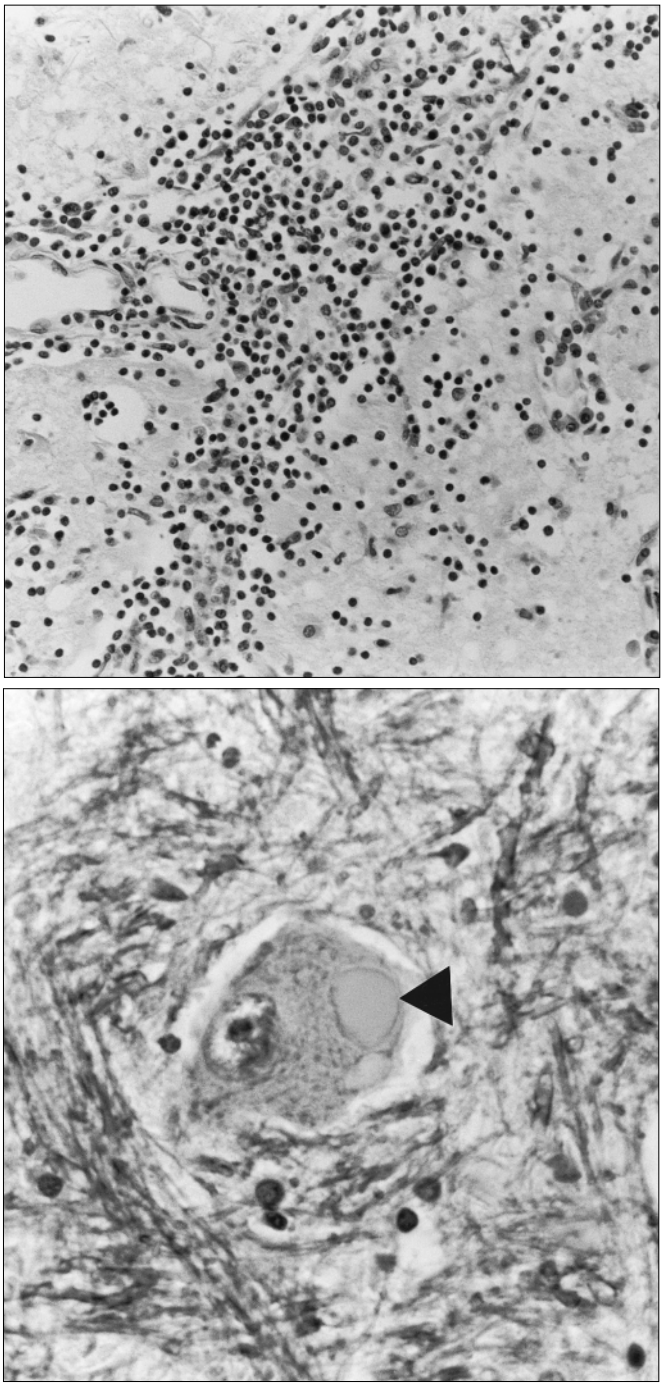

Fig. 1: Upper panel, photomicrograph of basal ganglia tissue with characteristic pattern of intense perivascular and infiltrative parenchymal mononuclear cell inflammation, chiefly lymphocytes and macrophages. (Staining with hematoxylin and eosin; original magnification × 200 reduced, by 25%.) Lower panel, brain stem neuron with demarcated cytoplasmic inclusion (arrowhead), consistent with a viral inclusion. (Original magnification × 600, reduced by 22%).

findings, and another patient had major right temporal lobe involvement.[16] Hemiplegia was the most common manifestation of neurologic damage; however, recurrent severe headaches,[9] minor memory impairment[22] and damage to the upper cervical cord, resulting in paralysis and the wasting of right shoulder muscles,[12] were also reported. Over half (11/20) of the patients who survived had sequelae, and this rate may actually be higher because follow-up information was not available on some cases.

This case report shows changes similar to those seen in the only other neuropathologically examined case — the first reported case — with an infectious viral meningoencephalitic pattern of changes, chiefly affecting grey matter throughout the brain, and associated with a chronic inflammatory reactive cellular infiltrate of lymphocytes and macrophages. Other similarities include the abundance of perivascular inflammatory cells and multiple foci of parenchymal cells centred in grey matter (Fig. 1, upper panel). In contrast to the initial case, the brain tissue of the patient in this case showed more intense inflammatory infiltrates associated with actual tissue necrosis in the most severely affected areas (i.e., basal ganglia and rostral brain stem). These areas were not associated with a true vasculitis. The lymphocytic reactive population comprised an approximate equal proportion of T and B lymphocytes. In both cases, the meningeal inflammatory component was relatively minor.

There were focal areas of tissue necrosis associated with the most intense areas of chronic inflammation. This can lead to clinical and radiologic confusion with herpes simplex encephalitis, particularly when temporal lobe involvement is present. The general prominence of grey matter pathology is in keeping with the known neurotropism of arthropod-borne viruses, and with Powassan virus in particular;[5,26,27] experimental studies have confirmed a high degree of viral neurotropism.[26,27] The accumulation of viral particles has been well demonstrated in neurons and, to a lesser degree, in glial cells. Neuronal accumulation is largely cytoplasmic.[27] Mechanisms of neuronal or cellular entry, including any putative membrane viral receptors, are currently unknown. The pathologic changes described here are also similar to those seen with other arboviruses, such as with the equine encephalidities and St. Louis viral encephalitis. Typically, viral inclusions are not found, although previous human neuropathologic examinations are limited to the initial case published in 1959. Ultrastructural examination failed to show viral particles in this case, and this was not unexpected given the marked sampling limitations and postmortem artifactual changes. Careful re-examination of the neuropathologic material showed a rare neuron with an eosinophilic inclusion which most likely represented a viral inclusion (Fig. 1, lower panel). Animal studies have also shown prominent pathologic involvement of spinal cord grey matter,[5] but the spinal cord was not available for pathologic examination in this case. However, in keeping with the marked grey matter involvement at higher levels of the neural axis, including the lower brain stem, it is quite reasonable to assume that myelitic inflammatory changes involving the spinal grey matter were present.[21] This may have been a contributing factor to the patient's flaccid paralysis.

There is currently no vaccine available for Powassan virus.[3,8,28] Education is the best possible defense; people should be aware of tick-borne diseases and learn to avoid any contact with suspected vectors. Human protection is mainly achieved through wearing adequate clothing to minimize exposed skin, treating clothes with insecticides and avoiding or clearing bushy areas. The use of tick repellents and insecticides should be encouraged, and an effort should be made to control ticks in domestic and farm animals and in buildings that they frequent.

It is important for health care providers to consider Powassan virus in the differential diagnosis of aseptic meningitis and encephalitis cases during the summer months. Serum samples should be obtained for serologic testing, and any confirmed cases should be promptly reported to the health authorities.[23]

Competing interests: None declared.

References

1. McLean DM, Donahue WL. Powassan virus: isolation of virus from a fatal case of encephalitis. *CMAJ* 1959;80:708-11.
2. McLean DM, Cobb C, Gooderham SE, Smart CA, Wilson AG, Wilson WE. Powassan virus: persistence of virus activity during 1966. *CMAJ* 1967;96:660-4.
3. Artsob H. Powassan encephalitis. In: Monath TP, editor. *The arboviruses: epidemiology and ecology*. vol 4. Boca Raton (FL): CRC Press; 1989. p. 29-49.
4. Wilson MS, Wherrett BA, Mahdy MS. Powassan virus meningoencephalitis: a case report. *CMAJ* 1979;121:320-3.
5. Little PB, Thorsen J, Moore W, Weninger N. Powassan virus encephalitis: a review and experimental studies in the horse and rabbit. *Vet Pathol* 1985; 22:500-7.
6. Whitney E. Arthropod-borne viruses in New York State: serologic evidence of Groups A, B and Bunyamwera viruses in dairy herds. *Am J Vet Res* 1965; 26:914-9.
7. Woodall JP, Roz A. Experimental milk-borne transmission of Powassan virus in the goat. *Am J Trop Med Hyg* 1977;26:190-2.
8. Calisher CH. Medically important arboviruses of the United States and Canada. *Clin Microbiol Rev* 1994;7(1):89-116.
9. Goldfield M, Austin SM, Black HC, Taylor BF, Altman R. A non-fatal human case of Powassan virus encephalitis. *Am J Trop Med Hyg* 1973;22:78-81.
10. Smith R, Woodall JP, Whitney E, Deibel R, Gross M, Smith V, et al. Powassan virus infection: a report of three human cases of encephalitis. *Am J Dis Child* 1974;127:691-3.
11. Rossier E, Harrison RJ, Lemieux B. A case of Powassan virus encephalitis. *CMAJ* 1974;110:1173-80.
12. Deibel R, Flanagan TD, Smith V. Central nervous system infections in New York State. Etiologic and epidemiologic observations, 1974. *N Y State J Med* 1975;75:2337-42.
13. Conway D, Rossier E, Spence L, Artsob A. Powassan virus encephalitis with shoulder girdle involvement. *Can Dis Wkly Rep* 1976;2:85-7.
14. Deibel R, Flanagan TD, Smith V. Central nervous system infections. Etiologic and epidemiologic observations in New York State, 1975. *NY State J Med* 1977;77:1398-1404.
15. Rossier E. Powassan encephalitis — Ontario. *Can Dis Wkly Rep* 1976;2:202-3.
16. Deibel R, Srihongse S, Woodall JP. Arboviruses in New York State: an attempt to determine the role of arboviruses in patients with viral encephalitis and meningitis. *Am J Trop Med Hyg* 1979;28:577-82.
17. Embil JA, Camfield P, Artsob H, Chase DP. Powassan virus encephalitis resembling herpes simplex encephalitis, *Arch Intern Med* 1983;143:341-3.
18. Joshua JM, Crapper DR, Spence L, Artsob H, Surgeoner G. A case of Powassan virus encephalitis — Ontario. *Can Dis Wkly Rep* 1979;5:129-30.
19. Partington MV, Thomson V, O'Shaughnessy MV. Powassan virus encephalitis in southeastern Ontario. *CMAJ* 1980;123:603-4.
20. Mahdy MS, Bansen E, McLaughlin B, Artsob H, Spence L, Bact D. Califor-

nia and Powassan virus disease in Ontario 1977–1980. *Can Dis Wkly Rep* 1982; 8:185-91.
21. Jackson AC. Leg weakness associated with Powassan virus infection — Ontario. *Can Dis Wkly Rep* 1989;15:123-4.
22. Fitch W, Artsob H. Powassan encephalitis in New Brunswick. *Can Fam Physician* 1990;33:1289-90.
23. Arboviral disease — United States, 1994. *MMWR* 1995;44(35):641-4.
24. Kolski H, Ford-Jones EL, Richardson S, Petric M, Nelson S, Jamieson F, et al. Etiology of acute childhood encephalitis at Hospital for Sick Children, Toronto, 1994–1995. *Clin Infect Dis* 1998;26:398-409.
25. McLean DM, MacPherson LW, Walker SJ, Funk G. Powassan virus: surveys of human and animal sera. *Am J Public Health* 1960;50:1539.
26. Frolova MP, Isachkova LM, Shestopalova NM, Pogodina VV. Experimental encephalitis monkeys caused by Powassan virus. *Neurosci Behav Physiol* 1985; 15(1):62-9.
27. Isachkova LM, Shestopalova NM, Frolova MP, Reingold VN. Light and electron microscope of the neurotropism of Powassan virus strain P-40. *Acta Virol* 1979;23(1):40-4.
28. Costero A, Grayson M. Experimental transmission of Powassan virus (flaviviridae) by *Ixodes scapularis* ticks (acari:ixodidae). *Am J Trop Med Hyg* 1996; 55(5):536-46.

Reprint requests to: *Dr. Bassam I.A. Gholam, Emergency Medicine Resident, McMaster University, 140 Robinson St., No. 903, Hamilton ON L8P 4R6; fax 905 387-3713; gholam@globalserve.net*